

Oral Health for USMLE Step One

Section 2: Oral Lesions



Lesions

1. Viral
2. Bacterial
3. Fungal
4. Vitamin Deficiency
5. **Autoimmune**
6. **Medication Induced**
7. Precancerous
8. Malignant Neoplasms



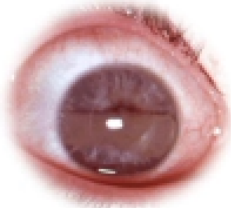*Olivia Nuelle, Medical School Class of 2022
University of Massachusetts Medical School
Faculty Adviser: Hugh Silk, MD
E-mail: Howard@12DaysinMarch
www.12DaysinMarch.com*

Oral Health for USMLE Step One

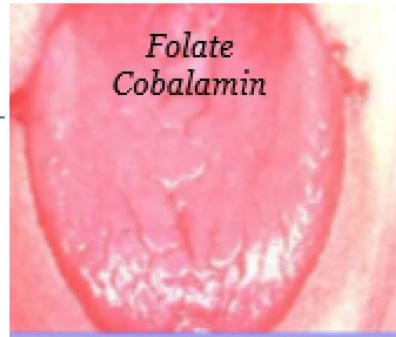
Section 2: Oral Lesions

Lesions

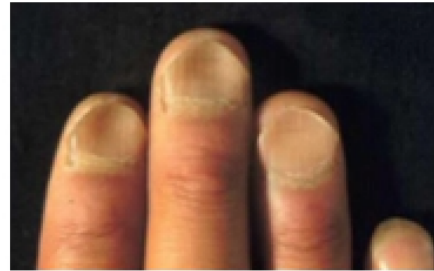Riboflavin



*Folate
Cobalamin*

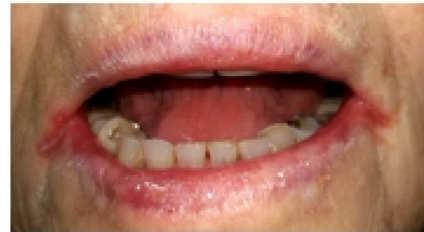

Iron

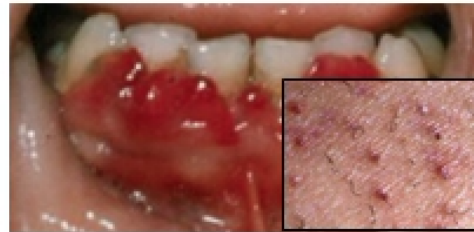

Vitamin Deficiency

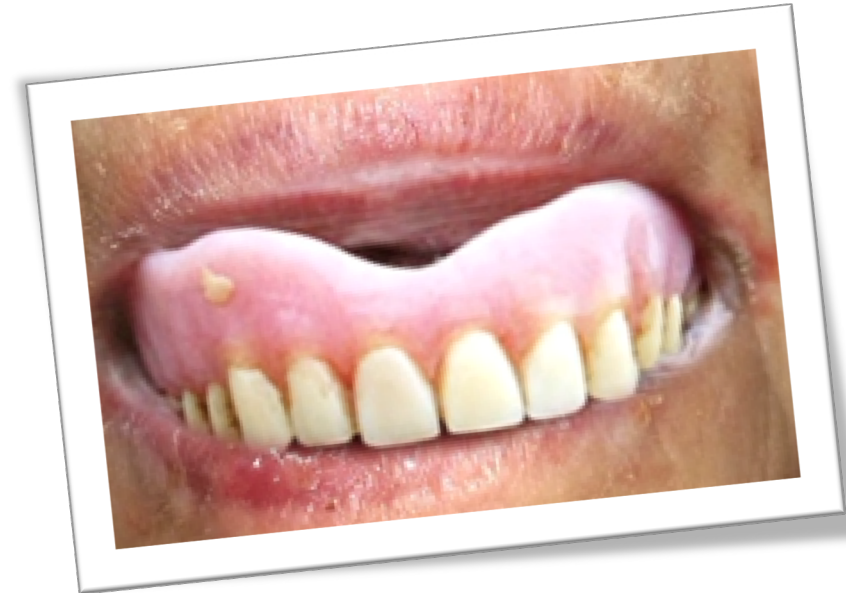1. Iron (microcytosis)
2. Riboflavin (corneal vascularization)
3. Folate/B12 (macrocytosis)
4. Vitamin C (Scurvy; collagen failure)



*Iron
Riboflavin
(Fungus)*



Vitamin C



Oral Health

for USMLE Step One

Pathology of the
Oral Cavity

Lesions

Congenital

Salivary
Pathology

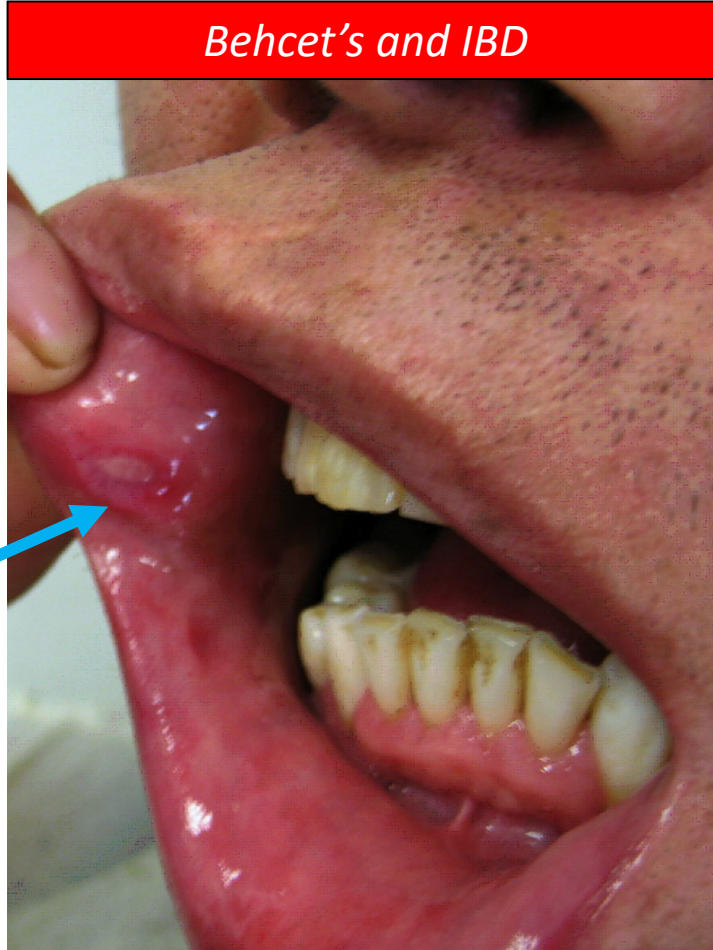Dental
Pathology

Other

1. Viral
2. Bacterial
3. Fungal
4. Nutritional Deficiency
- 5. Autoimmune**
6. Medication Induced
7. Precancerous
8. Malignant Neoplasms

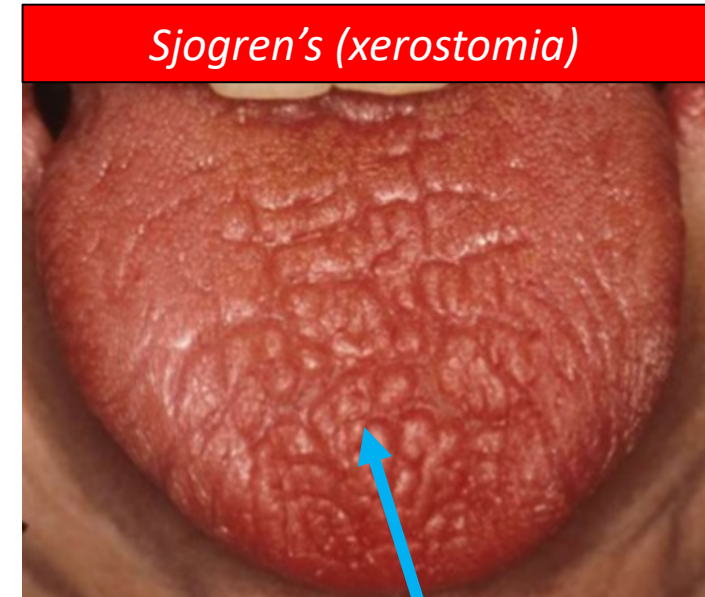Autoimmune Lesions of the Oral Cavity

Behcet's and IBD



Aphthous Ulcers

Sjogren's (xerostomia)

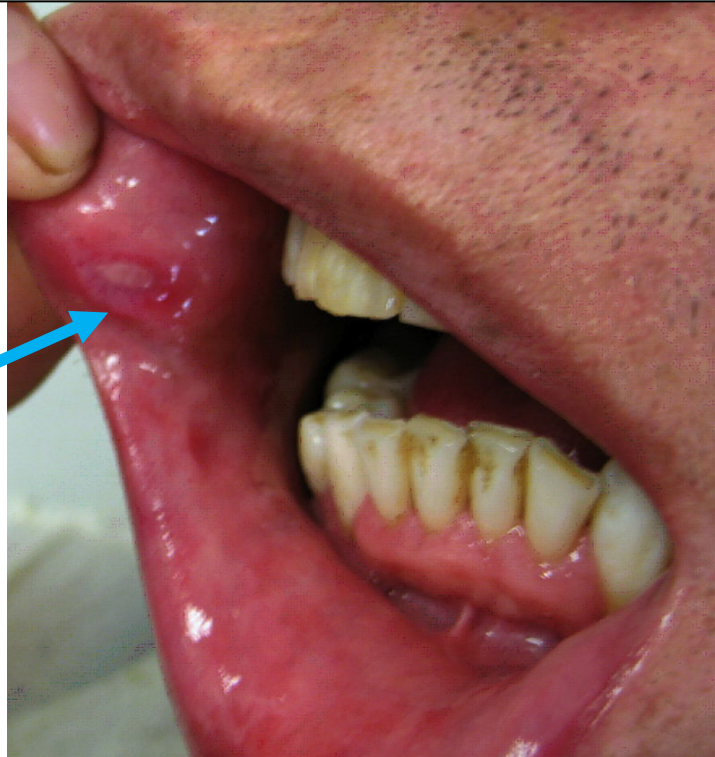

Fissured Tongue

Autoimmune Lesions of the Oral Cavity

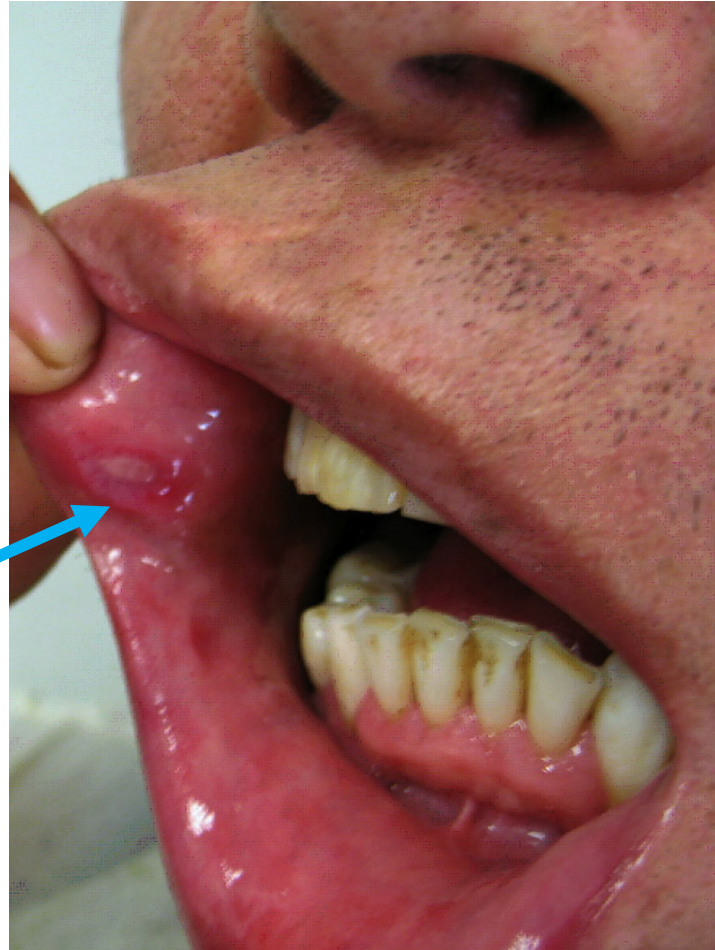'Canker sore'

- *Single lesion*
- *Absence of systemic symptoms*



Aphthous Ulcers

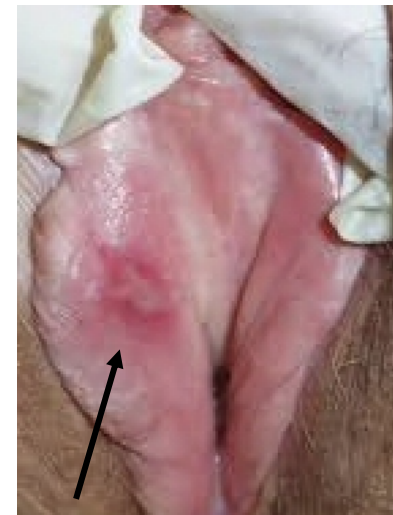Autoimmune Lesions of the Oral Cavity



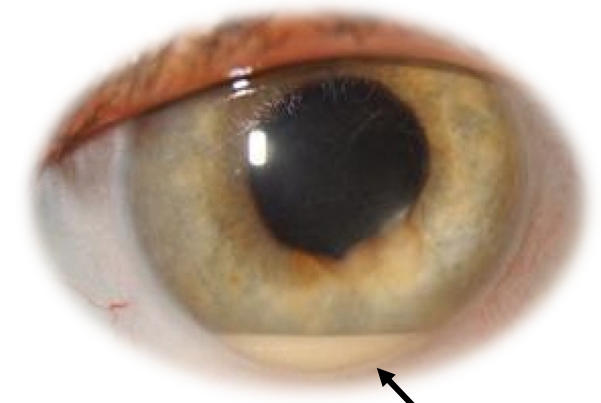
Aphthous Ulcers

Behcet's (triad)

1. Recurrent aphthous ulcers
2. Genital ulcers
3. Uveitis

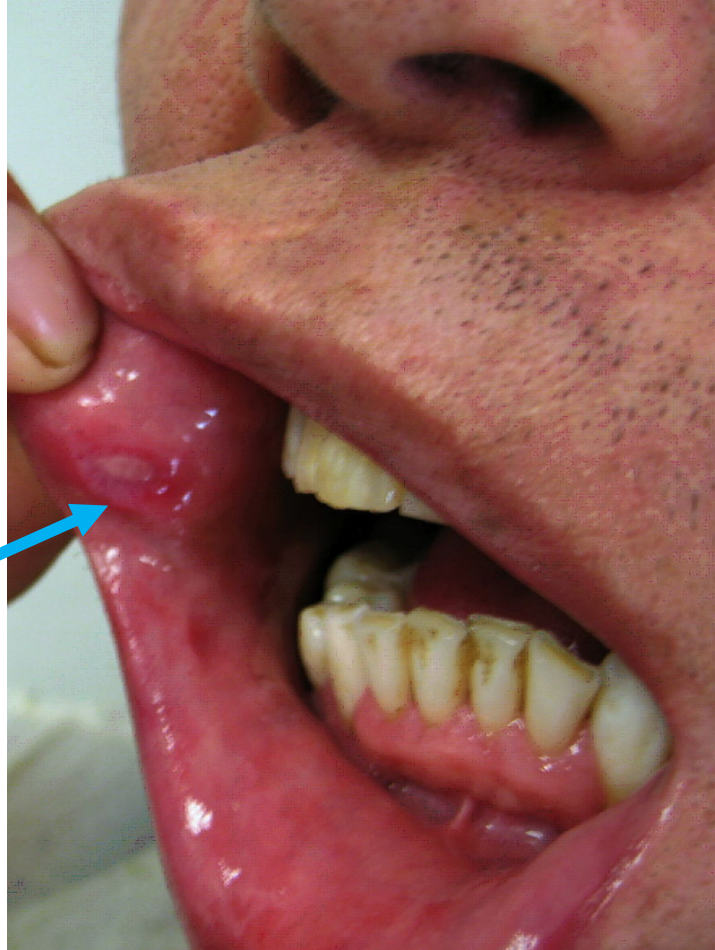

Ulcer



Uveitis

Autoimmune Lesions of the Oral Cavity



Aphthous Ulcers

Behcet's (triad)

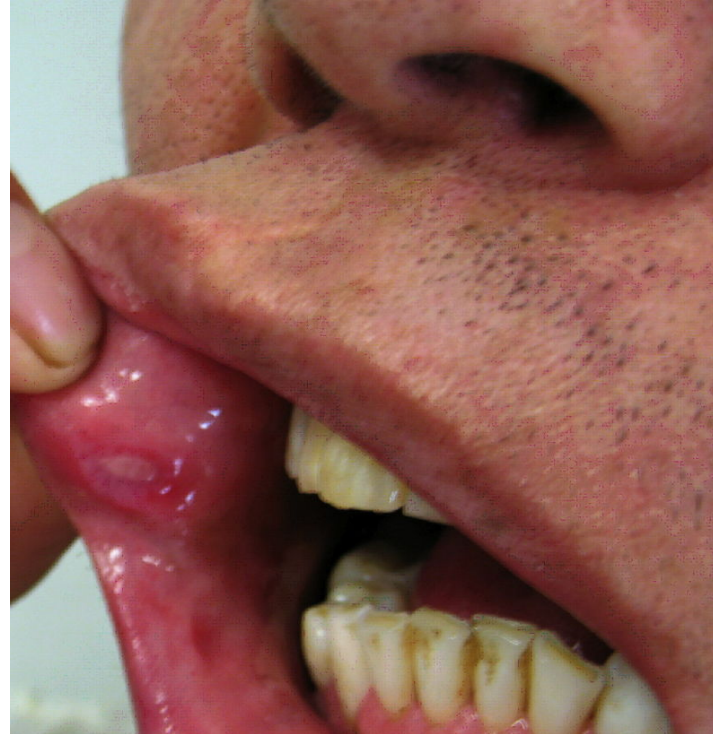- 1. Recurrent aphthous ulcers**
- 2. Genital ulcers**
- 3. Uveitis**

- Immune complex vasculitis**

Autoimmune Lesions of the Oral Cavity

Behcet's (triad)

1. Recurrent aphthous ulcers
2. Genital ulcers
3. Uveitis

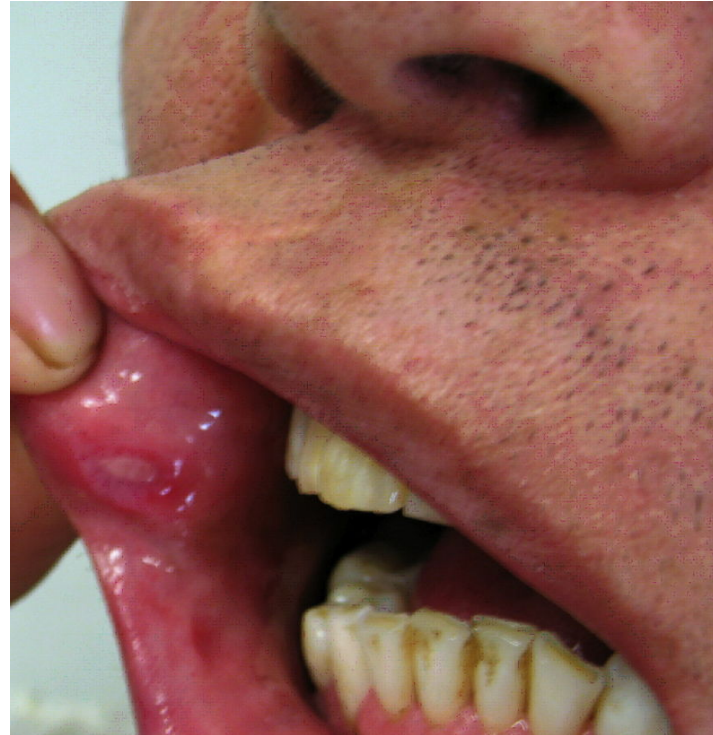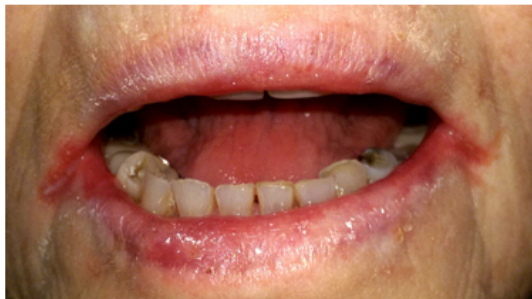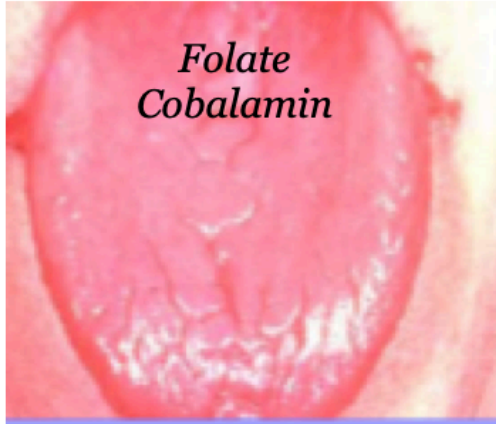


Aphthous ulcers are the oral manifestation of these two multisystem inflammatory disorders

Inflammatory Bowel Disease (IBD)

- Diarrhea
- Hematochezia
- Abdominal pain

Autoimmune Lesions of the Oral Cavity



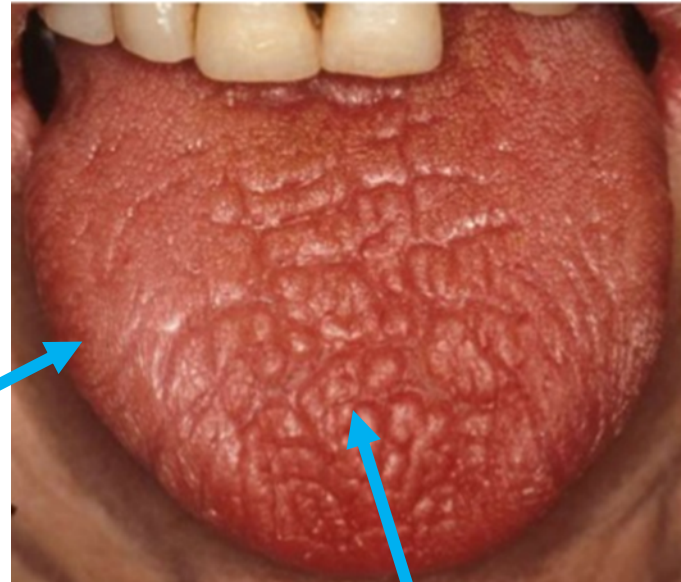Aphthous ulcers are the oral manifestation of these two multisystem inflammatory disorders

Inflammatory Bowel Disease (IBD)

- Diarrhea
- Hematochezia
- Abdominal pain

Autoimmune Lesions of the Oral Cavity

Sjogren Syndrome



Fissured Tongue

Autoimmune Lesions of the Oral Cavity



Sjogren Syndrome

Fissured Tongue

- Dry Eyes
- Dry Mouth
- Nonerosive Arthritis

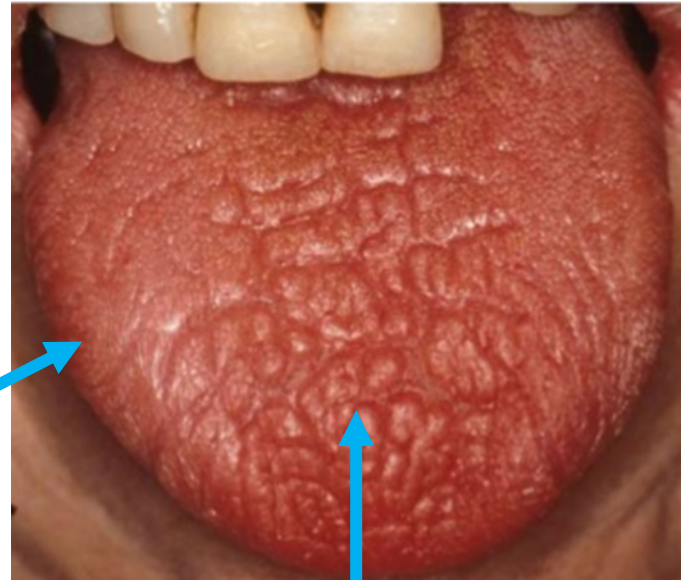
Autoimmune Lesions of the Oral Cavity

Pathology:

Autoimmune destruction of salivary and lacrimal glands

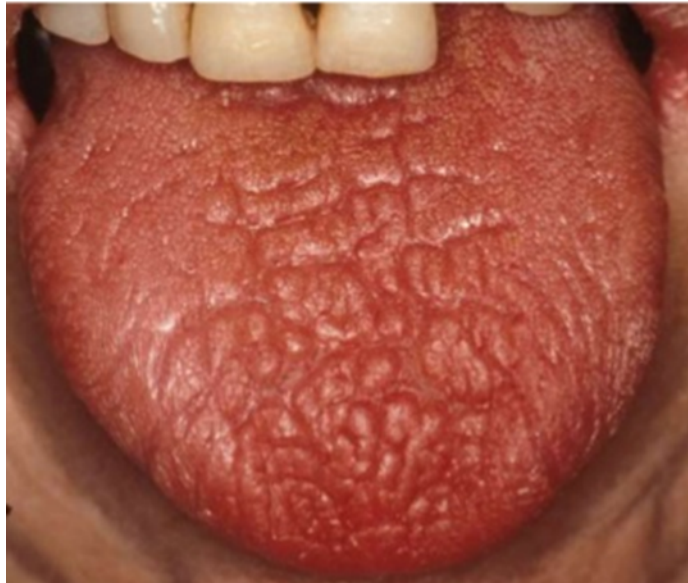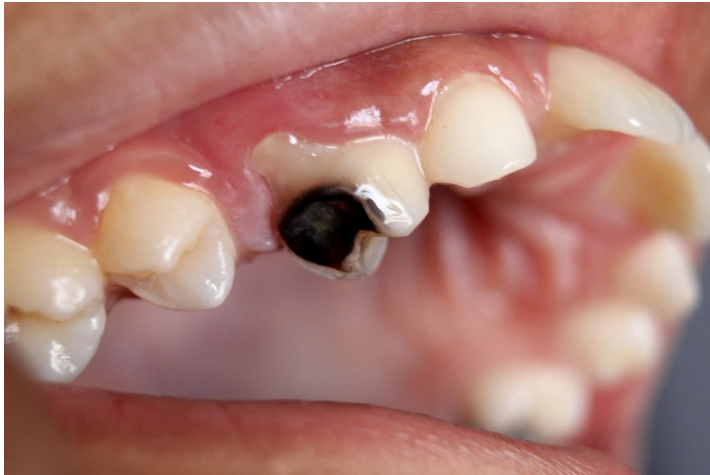- Dry Eyes
- Dry Mouth
- Nonerosive Arthritis

Sjogren Syndrome



Fissured Tongue
2° to **Xerostomia**

Autoimmune Lesions of the Oral Cavity



Pathology:
Autoimmune destruction of salivary and lacrimal glands

- Dry Eyes
- Dry Mouth
- Nonerosive Arthritis

Saliva buffers this...



SSA & SSB (SJOGREN'S) Antibodies		
	Ref Range & Units	Value
Sjogren'S Antibody	<1.0 NEG AI	<1.0 NEG
Sjogren'S Antibody	<1.0 NEG AI	5.5 POS ^

Ribonucleoproteins

Oral Health

for USMLE Step One

Pathology of the
Oral Cavity

Lesions

Congenital

Salivary
Pathology

Dental
Pathology

Other

Autoimmune

1. Behcet's (genital ulcers, uveitis)
2. IBD (diarrhea)
3. Sjogren's (xerostomia, arthralgia)

Oral Health

for USMLE Step One

Pathology of the
Oral Cavity

Lesions

Congenital

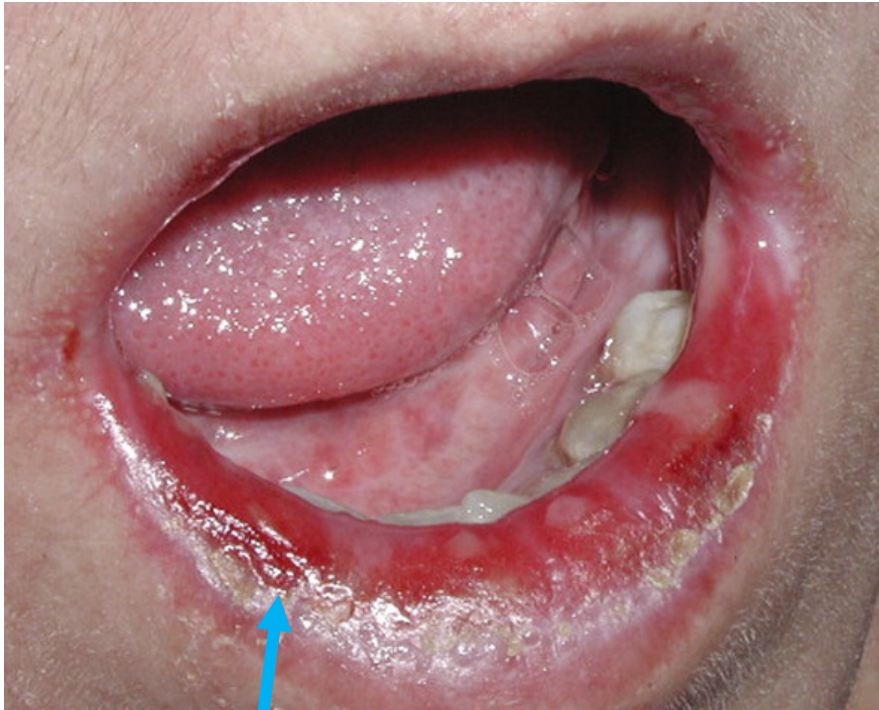Salivary
Pathology

Dental
Pathology

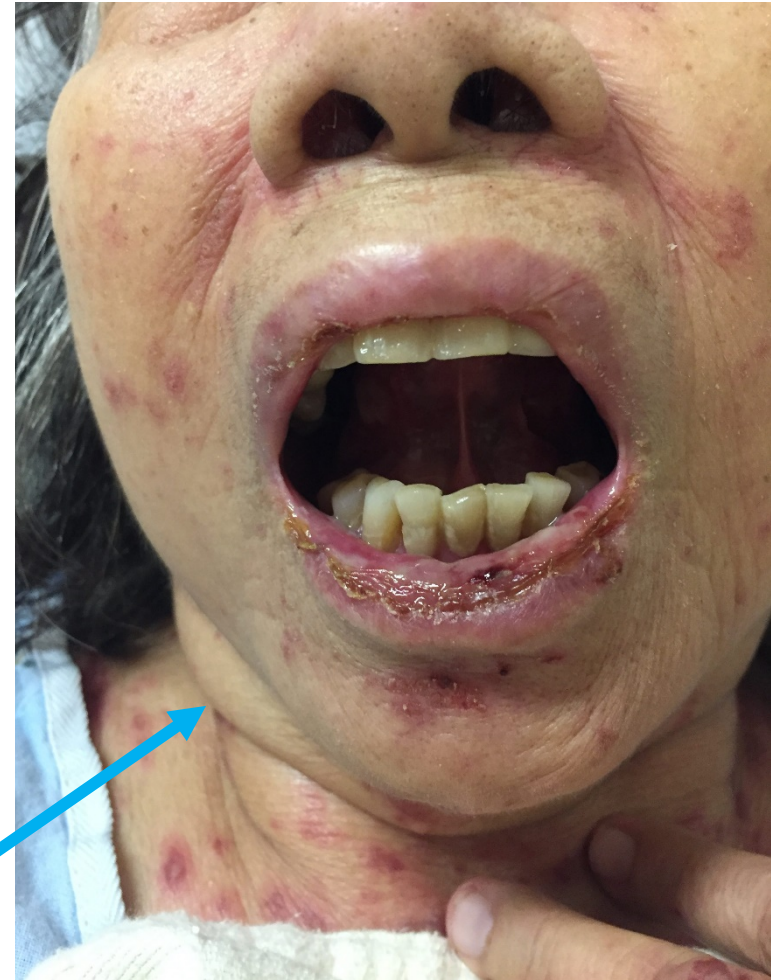Other

1. Viral
2. Bacterial
3. Fungal
4. Nutritional Deficiency
5. Autoimmune
6. Medication Induced
7. Precancerous
8. Malignant Neoplasms

Medication Induced Lesions of
the Oral Cavity



Erythema Multiforme



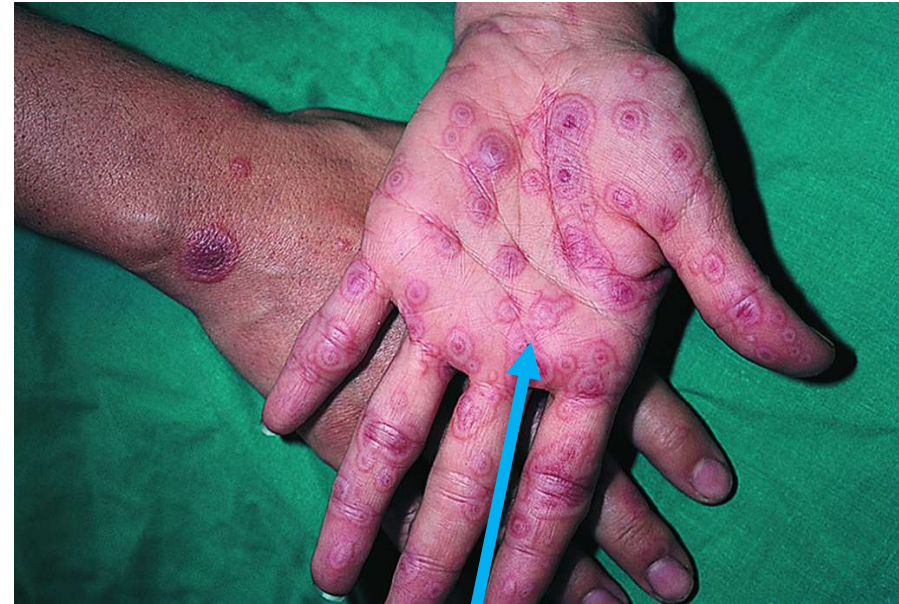Stevens-Johnson syndrome

Medication Induced Lesions of the Oral Cavity



Erythema Multiforme

Targetoid lesions

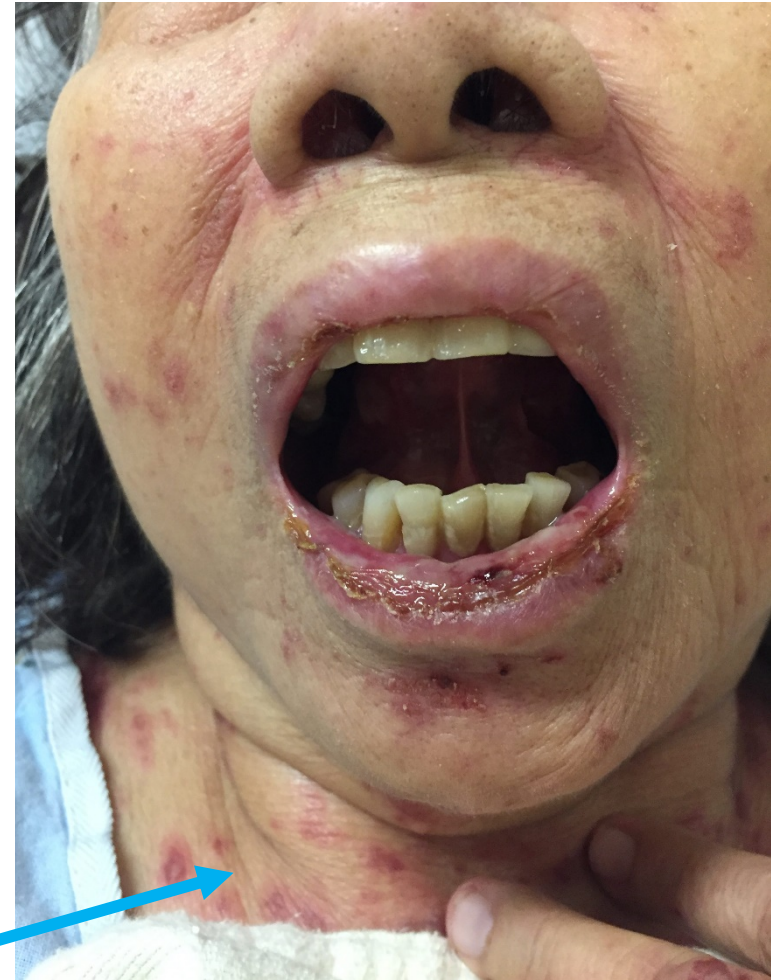
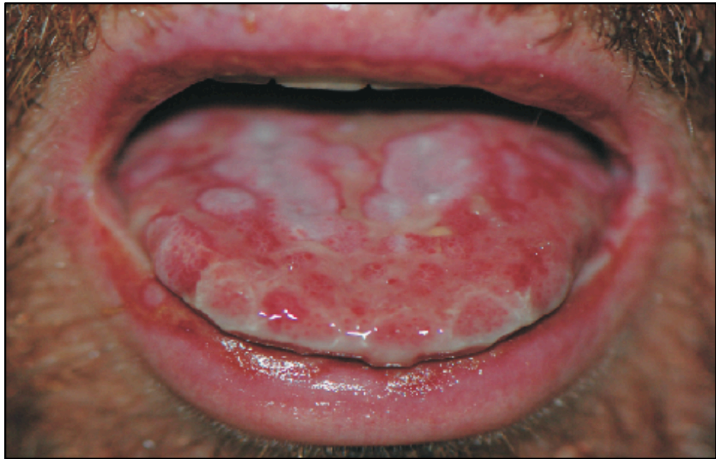
Mosby's Medical Dictionary, 9th edition. © 2009, Elsevier.

**Lesions on skin (acral) and oral mucosa
Acute onset, self-limited**

Medication Induced Lesions of the Oral Cavity

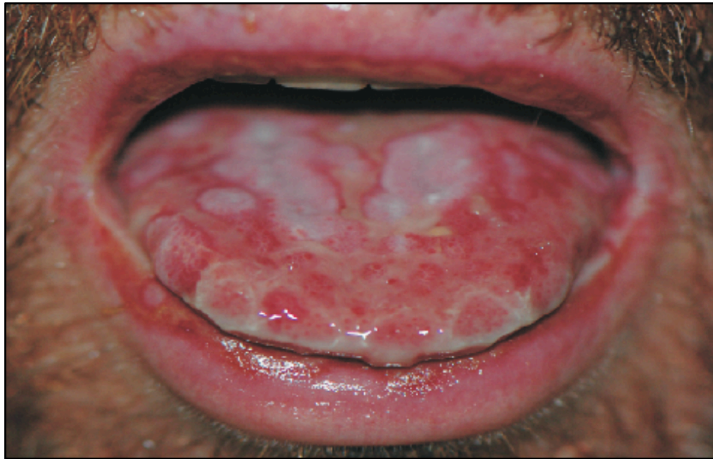- Blistering skin, erosions and **skin pain**
- Oral lesions: **sloughing/crusting in 100%**
- Ocular lesions (conjunctivitis) commonly present
- Fever
- High mortality rate



Stevens-Johnson syndrome

Medication Induced Lesions of the Oral Cavity

- Blistering skin, erosions and skin pain
- Oral lesions: sloughing/crusting in 100%
- Ocular lesions (conjunctivitis) commonly present
- Fever
- High mortality rate
- **Medications: Allopurinol, Seizure Drugs, NSAIDs**
- **Days to weeks** after exposure



Stevens-Johnson syndrome

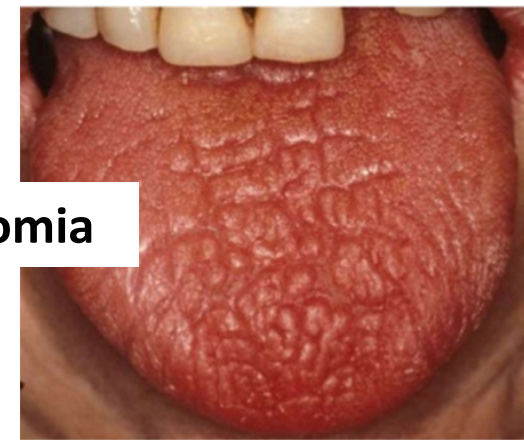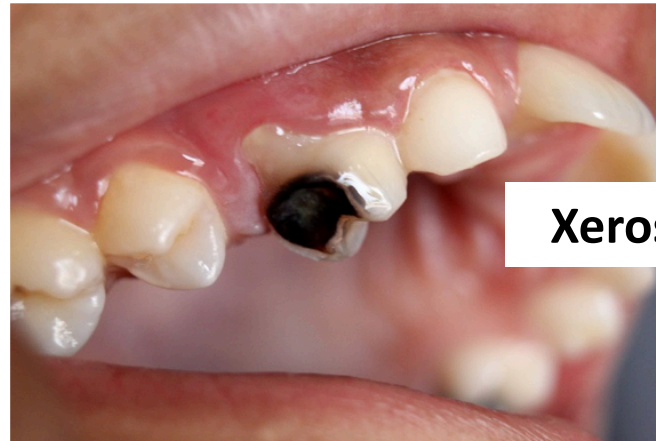Oral Health

for USMLE Step One

Pathology of the
Oral Cavity

Lesions

1. Viral
2. Bacterial
3. Fungal
4. Nutritional Deficiency
5. Autoimmune
6. Medication Induced
7. Precancerous
8. Malignant Neoplasms



Xerostomia

Saliva buffers this...



Oral Health

for USMLE Step One

Pathology of the
Oral Cavity

Lesions

Congenital

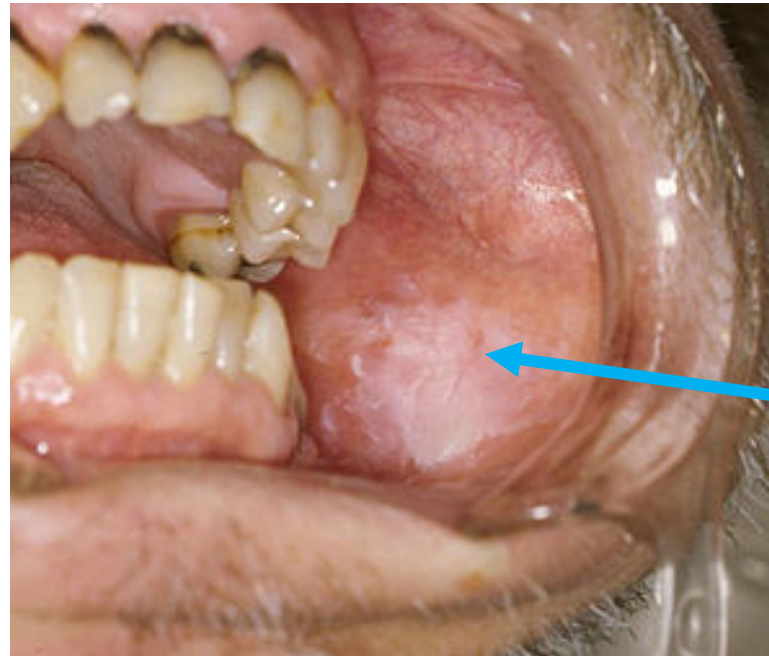
Salivary
Pathology

Dental
Pathology

Other

1. Viral
2. Bacterial
3. Fungal
4. Nutritional Deficiency
5. Autoimmune
6. Medication Induced
- 7. Precancerous**
8. Malignant Neoplasms

Precancerous Lesions of the Oral Cavity

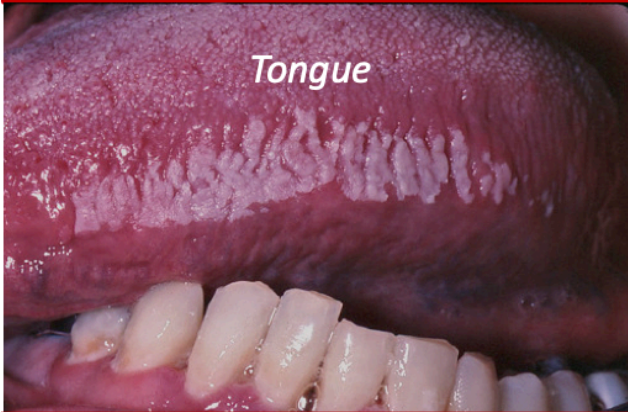

Leukoplakia

- White plaque with well-demarcated borders
- **CANNOT** be removed
- CAN be found **anywhere** in the oral cavity

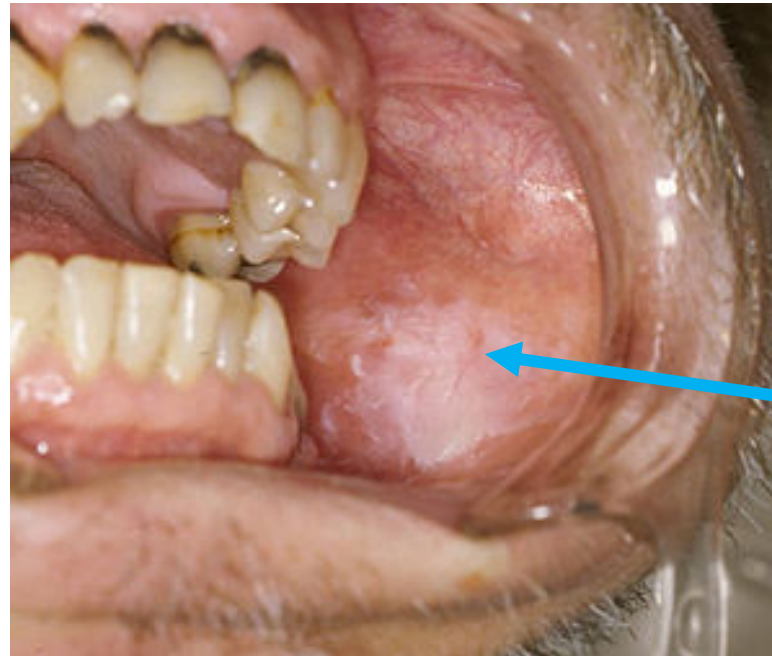
Precancerous Lesions of the Oral Cavity

Epstein Barr Virus (EBV)
(HH-4; enveloped, DS DNA)



Oral Hairy Leukoplakia

- White plaque on the **lateral** tongue
- **CANNOT** be scraped off
- Benign



Leukoplakia

- White plaque with well-demarcated borders
- **CANNOT** be removed
- **CAN** be found **anywhere** in the oral cavity

Oral Health

for USMLE Step One

Pathology of Oral
Cavity

Lesions

Congenital

Salivary
Pathology

Dental
Pathology

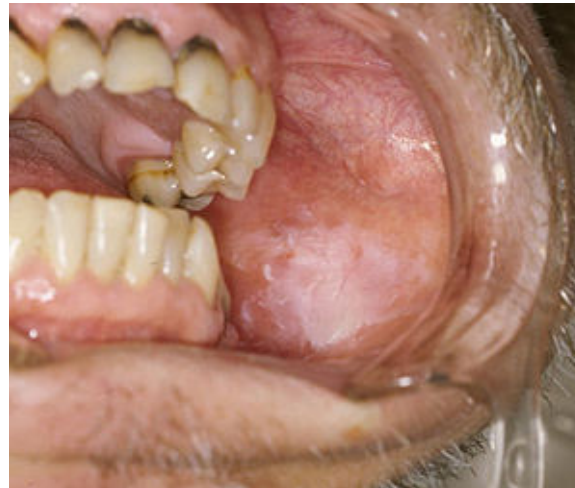Other

1. Viral
2. Bacterial
3. Fungal
4. Nutritional Deficiency
5. Autoimmune
6. Medication Induced
7. Precancerous
8. **Malignant Neoplasms**



Oral Health for USMLE Step One

Section 2: Oral Lesions



*Olivia Nuelle, Medical School Class of 2022
University of Massachusetts Medical School
Faculty Adviser: Hugh Silk, MD
E-mail: Howard@12DaysinMarch
www.12DaysinMarch.com*